CASE OF THE MONTH-APRIL 2026	
HealthTech WOUND CARE	Clinical
	Document Number: HT-CLN-MKT-28
	Revision: 0

CASE OF THE MONTH

Stage 3 Heel Pressure Ulcer –Treated with DermaBind FM

Patient Overview

A 68-year-old male with a complex medical history, including end-stage renal disease (ESRD), mixed hyperlipidemia, hypothyroidism, chronic pain syndrome, and a history of cigar smoking, became wheelchair dependent following a recent aortic valve replacement and subsequent skilled nursing facility rehabilitation. In April 2025, while self-propelling his wheelchair, the patient developed a Stage 3 pressure ulcer on his right heel. He presented on 6/18/25 with an eight-week-old, non-healing ulcer.

Failed Standard of Care

The patient underwent > 30 days of standard of care, which included nutritional optimization, moist wound care, infection management, serial sharp debridement, medi-honey, calcium alginate dressings and offloading. Despite these measures, the ulcer showed no evidence of healing. Due to a lack of improvement, the provider determined the wound was appropriate for advanced treatment with an allograft. Vascular studies were completed but unavailable for the case study report.

Treatment

The ulcer was cleansed throughout the course of care with Dermal Wound Cleanser, SKIN-PREP applied initially for peri wound protection. DermaBind was applied weekly and secured with a contact layer and steri-strips, then covered with bordered foam and a Kerlix wrap. Offloading with a heel boot was required at all times. Outer dressings could be changed if soiled, provided the contact layer remained undisturbed. As drainage decreased, outer dressings were left in place for the full week. Once the wound approached near-complete re- epithelialization, therapy transitioned to Collagen Ag+ with foam and gauze for one additional week until full resolution.

Findings

The patient underwent **six DermaBind FM applications**, then transitioned to standard of care for just over one week. The wound continued to progress and ultimately achieved full resolution, with 100% re-epithelialization documented on 8/15/25.

Property of HealthTech Wound Care *. **CONFIDENTIAL**. Unauthorized distribution or copying is prohibited

CASE OF THE MONTH-APRIL 2026

HealthTech WOUND CARE

Clinical

Document Number	HT-CLN-MKT-28
Revision	0

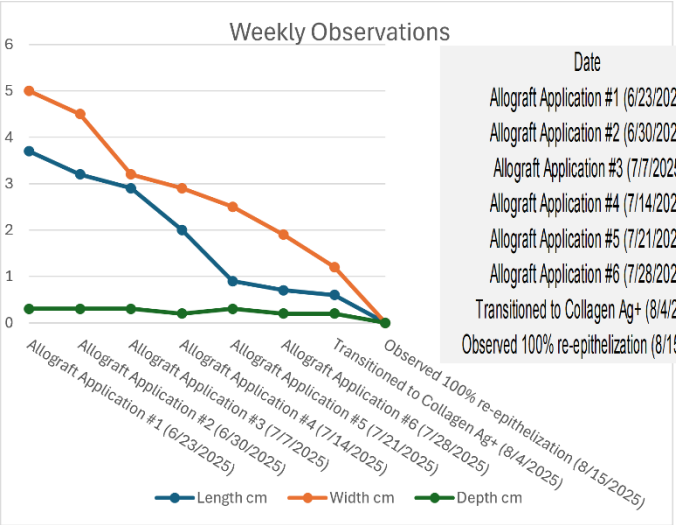

Date	Length cm	Width cm	Surface Area cm²	Depth cm	Volume cm³
Allograft Application #1 (6/23/2025)	3.7	5	18.5	0.3	5.55
Allograft Application #2 (6/30/2025)	3.2	4.5	14.4	0.3	4.32
Allograft Application #3 (7/7/2025)	2.9	3.2	9.28	0.3	2.78
Allograft Application #4 (7/14/2025)	2	2.9	5.8	0.2	1.16
Allograft Application #5 (7/21/2025)	0.9	2.5	2.25	0.3	0.67
Allograft Application #6 (7/28/2025)	0.7	1.9	1.33	0.2	0.26
Transitioned to Collagen Ag+ (8/4/2025)	0.6	1.2	0.72	0.2	0.14
Observed 100% re-epithelization (8/15/2025)	0	0	0	0	0

Property of HealthTech Wound Care *. **CONFIDENTIAL**. Unauthorized distribution or copying is prohibited

CASE OF THE MONTH-APRIL 2026

HealthTech WOUND CARE

Clinical	
Document Number	HT-CLN-MKT-28
Revision	0

Before & After Wound Images

Right Heel
Taken: 6/18/25

Lateral Right Heel
Taken: 6/23/25

Lateral Right Heel
Taken: 6/30/25

Lateral Right Heel
Taken: 7/07/25

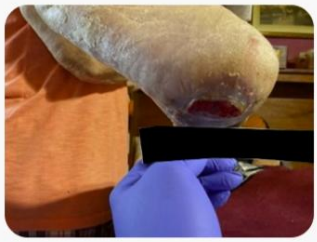

Right Heel
Taken: 7/14/25

Lateral Right Heel
Taken: 7/21/25

Lateral Right Heel
Taken: 7/28/25

Lateral Right Heel
Taken: 8/04/25

Right Heel
Taken: 8/15/25

Property of HealthTech Wound Care *. **CONFIDENTIAL**. Unauthorized distribution or copying is prohibited

Ethical approval and patient consent

Institutional Review Board approval was not required for this one patient case as patient had already been treated by their provider with DermaBind based on medical necessity and failed conservative treatment. Patient consent was obtained by their provider for the use and release of deidentified data, and publication of photographs/images.

References

Mendivil, J., McMahon, A. E., Ojelade, O. T., Hobson, K., Marballie, M., Alvarez, S., Adu-Aboagye, V., Chiamba, G., Gowdie, D., Landrum, W. E. II, Alzindani, A., Yazdani, H., Petty, G., Simard, M.-C., Schmid, D., & Meadors, J. (2025). Clinical use of DermaBind TL/FM as a wound covering for hard-to-heal wounds of various aetiologies: A case series. *Journal of Wound Care, 34*(11). https://doi.org/10.12968/jowc.2025.0448

Provider Information

Provider Name: Willie E. Landrum II, MD, WCC

Property of HealthTech Wound Care *. **CONFIDENTIAL**. Unauthorized distribution or copying is prohibited